

# AcrySof Phakic Angle-supported Intraocular Lens for the Correction of Moderate-to-High Myopia: One-Year Results of a Multicenter European Study

Thomas Kohnen, MD,<sup>1</sup> Michael C. Knorz, MD,<sup>2</sup> Béatrice Cochener, MD,<sup>3</sup> Ralf H. Gerl, MD,<sup>4</sup> Jean-Louis Arné, MD,<sup>5</sup> Joseph Colin, MD,<sup>6</sup> Jorge L. Alió, MD,<sup>7</sup> Roberto Bellucci, MD,<sup>8</sup> Antonio Marinho, MD<sup>9</sup>

**Purpose:** To investigate the safety and effectiveness of the AcrySof phakic angle-supported intraocular lens (IOL) (Alcon Laboratories, Inc., Fort Worth, TX) for correction of moderate-to-high myopia in adults.

**Design:** One-year interim analysis of a phase 3, nonrandomized, open-label, prospective, multicenter European clinical study.

**Participants:** A total of 190 subjects (190 eyes) with moderate-to-high myopia. The preoperative mean manifest refraction spherical equivalent (MRSE) was  $-10.38$  diopters (D)  $\pm 2.43$  standard deviation (SD).

**Methods:** Unilateral implantation of the AcrySof phakic angle-supported IOL.

**Main Outcome Measures:** Best spectacle-corrected visual acuity (BSCVA), uncorrected distance visual acuity (UCVA), predictability and stability of MRSE, adverse events, and endothelial cell density.

**Results:** Of 190 subjects enrolled, 161 completed the 1-year postoperative visit. No subjects lost  $\geq 2$  lines BSCVA. A UCVA of 20/20 or better was achieved by 57.8%; 99.4% had 20/40 or better. A BSCVA of 20/32 or better was achieved by 100% of subjects; 85.7% had 20/20 or better. The mean MRSE was  $-0.23$  D ( $\pm 0.50$  D:  $-2.50$  to  $0.75$  D). Residual refractive error was within  $\pm 1.0$  D from the target for 95.7% of subjects and within  $\pm 0.5$  D for 72.7% of subjects. The overall mean percentage change in central endothelial cell density 1 year after surgery was  $-4.77 \pm 8.04\%$  ( $n = 139$ ). No pupil ovalization, pupillary block, or retinal detachment events were observed.

**Conclusions:** The AcrySof phakic angle-supported IOL yielded excellent refractive correction and predictability with acceptable safety in subjects with moderate-to-high myopia. These 1-year interim analysis findings demonstrate preliminary support for the safety and efficacy of this IOL.

**Financial Disclosure(s):** Proprietary or commercial disclosure may be found after the references. *Ophthalmology* 2009;116:1314–1321 © 2009 by the American Academy of Ophthalmology.

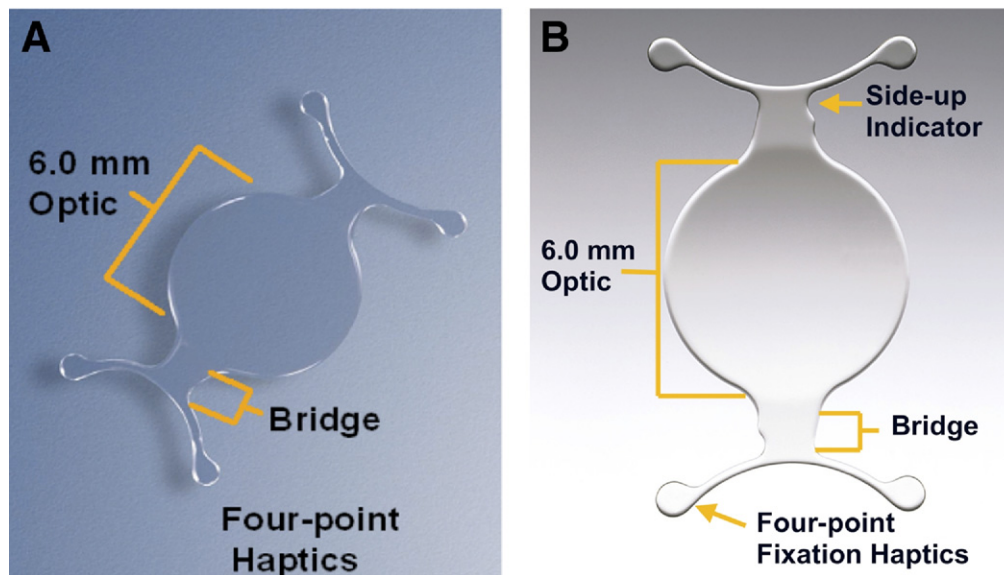


The correction of moderate-to-high myopia remains challenging. Corrective options such as spectacles and contact lenses are often unsatisfactory to patients, and many of these patients have refractive errors outside the range of treatment with laser ablation refractive surgery. In an effort to develop a refractive surgical option for patients with moderate-to-high myopia, phakic intraocular lenses (IOLs) of various designs and materials have been placed in the anterior chamber, fixed to the iris, and placed in the posterior chamber. Phakic IOLs have demonstrated excellent refractive results but have also been associated with safety concerns.<sup>1–9</sup> A fundamental goal in phakic IOL development is to reduce potential risk while providing patients with moderate-to-high myopia visual correction, comfort, and convenience not attainable with spectacles or contact lenses.

The primary safety concerns associated with angle-supported anterior chamber phakic IOLs are corneal endothelial cell loss and pupil ovalization.<sup>1</sup> Published case re-

ports and clinical studies of up to 12 years duration found endothelial cell density changes ranging from significant losses to long-term gains, with recent publications generally describing smaller losses or gains compared with preceding reports.<sup>1–6,10–13</sup> A high frequency of pupil ovalization and IOL rotation has been associated with an early investigational angle-supported anterior chamber phakic IOL.<sup>14</sup> This lens has demonstrated satisfactory refractive results but is less widely accepted because of pupil ovalization and IOL rotation associated with IOL footplate displacement.

The AcrySof phakic angle-supported IOL (Alcon Laboratories, Inc., Fort Worth, TX) is made of foldable hydrophobic acrylate, permitting a small corneal incision size ( $\sim 3.0$  mm) using the Monarch II IOL Delivery System with the “B” or “C” cartridge. The haptics are designed to permit compression within the angle for IOL stability (data on file, Alcon Research, Ltd.), without creating excessive force that could cause angle tissue damage or pupil ovalization. Mod-



**Figure 1.** The AcrySof angle-supported phakic intraocular lens (IOL) (Alcon Laboratories, Inc., Fort Worth, TX). **A**, Implanted model. **B**, Modified version with the “side-up indicator”, which is a recent improvement; the IOLs implanted during this study did not have this indicator.

els of varying diameter allow fit within a variety of anterior chamber dimensions. The IOL is vaulted to provide optimal central clearance distance between the IOL and the cornea and the natural crystalline lens. These characteristics are intended to achieve predictable implantation, stable vaulting, and low compression forces on the angle, while minimizing corneal endothelial cell loss, pupil ovalization, and cataract formation. This article describes the 1-year interim analysis results of a 5-year investigation of the AcrySof phakic angle-supported IOL for the correction of moderate-to-high myopia in adult subjects.

## Subjects and Methods

### Subject Recruitment

The study included 190 adult subjects with good general and ocular health and moderate-to-high myopia (range,  $-6.0$  to  $-16.5$  diopters [D]) in the intended operative eye. Eligibility criteria included a preoperative best spectacle-corrected visual acuity (BSCVA) of  $+0.3$  logarithm of the minimum angle of resolution (logMAR) or better and refraction within  $\pm 0.5$  D at least 12 months before surgery, as determined by the manifest refraction spherical equivalent (MRSE).

Exclusion criteria included an anterior chamber depth  $< 3.2$  mm (including the corneal epithelium), history of corneal or intraocular surgery (e.g., laser coagulation of retinal defects), mesopic pupil diameter  $> 7.0$  mm, astigmatism  $> 2.0$  D, or cataract of any type or degree. Subjects were also excluded for nonqualifying preoperative endothelial cell density according to age-based protocol-specified criteria (i.e.,  $< 2800$  cells/mm<sup>2</sup>, age 18–25 years;  $< 2600$  cells/mm<sup>2</sup>, age 26–35 years;  $< 2200$  cells/mm<sup>2</sup>, age 36–45 years; and  $< 2000$  cells/mm<sup>2</sup>, age  $\geq 46$  years; Refractive Implants: Investigational Device Exemptions and Premarket Approval Applications; U.S. Food and Drug Administration, Draft August 1, 2000).

Subjects provided written, informed consent before participating in the study. Local ethics committees approved the study

before its commencement. Study conduct adhered to local and regional regulations, good clinical practices, and the tenets of the Declaration of Helsinki.

### AcrySof Phakic Angle-supported Intraocular Lens

The AcrySof phakic IOL is a single-piece, foldable, soft acrylic lens with a chemically bonded ultraviolet chromophore (acrylate/methacrylate co-polymer) and is intended for implantation in the anterior chamber angle (Fig 1). This study included 3 IOL models (L12500, L13000, and L13500), each with a different overall length (12.5, 13.0, and 13.5 mm, respectively). All models have a 6.0-mm meniscus optic and were available in half-diopter increments from  $-6.0$  to  $-16.5$  D.

### Preoperative Examination

A detailed subject health history and pregnancy test were performed to assess eligibility and general and ocular health. Best spectacle-corrected visual acuity was measured to the smallest line using an Early Treatment of Diabetic Retinopathy Study (ETDRS) visual acuity chart at 4 m under photopic lighting conditions (chart luminance was  $\sim 180$  cd/m<sup>2</sup>). Manifest refraction was performed using a 100% contrast ETDRS chart at 4 m under photopic lighting conditions (chart luminance was  $\sim 180$  cd/m<sup>2</sup>). To ensure consistency among study centers, lighting conditions were measured using the Gossen Starlite photometer (Gossen Foto und-Lichtmeßtechnik GmbH, Nürnberg, Germany). Equipment was calibrated before the initiation of the study and monitored over the course of the study at the start and end of each day. Subjects were manually refracted to their best correction using a phoropter or trial lenses.

Preoperative ocular examinations also included assessment of uncorrected near visual acuity at best distance, best-corrected near visual acuity at 40 cm, mesopic pupil size, cycloplegic refraction, axial length, anterior chamber depth, “target” residual refractive error, tonometry (Goldmann applanation method), pachymetry, manual keratometry, slit-lamp examination, indirect/direct ophthalmoscopy (dilated fundus examination), gonioscopic examination, endothelial cell density analysis, and a crystalline lens assessment using

Lens Opacities Classification System III, a subjective, standardized cataract grading method.<sup>15</sup>

For purposes of lens size selection and eligibility determination, the anterior chamber diameter was measured preoperatively as the width of the cornea from the nasal limbus to the temporal limbus (white-to-white measurement). This was measured with calipers, a Zeiss IOL Master (Carl Zeiss AG, Oberkochen, Germany), or an Orbscan II topographer (Bausch & Lomb, Rochester, NY).

Gonioscopic examination was performed by using the instrument of the physician's choice. The examination included assessment for anterior chamber angle recession, angle trauma, or anatomic anomalies.

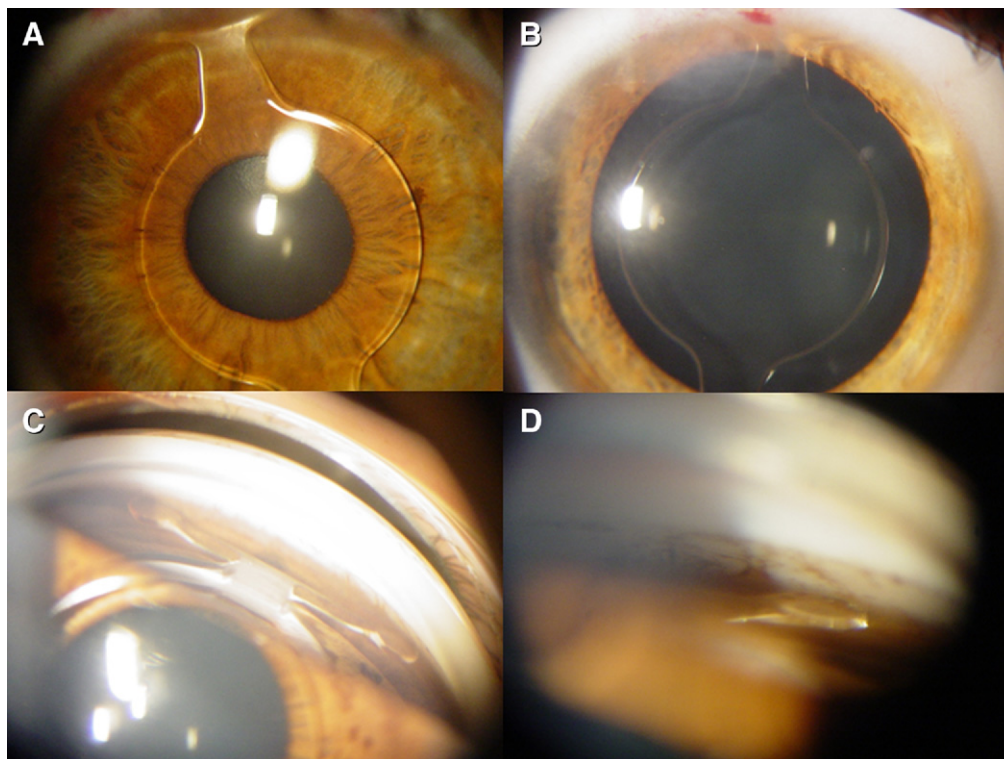
Endothelial images were taken at the corneal center (3 images) using the Konan Noncon-Robo specular microscope (Konan Medical, Inc., Hyogo, Japan). To minimize analysis variability, a noncontact specular microscope was used at each site, standardized training was provided with skill assessment to ensure quality images, and a centralized reading center (Alcon Research, Ltd.) performed endothelial cell analyses. Images sent to the reading center were analyzed using the center method (Konan analysis software). In the center method, the computer mouse is used to dot the center of the cells in the digital images. At least 100 contiguous cells were marked on the image to obtain an analysis of at least 50 cells. The cell counts of 2 to 3 images were averaged to calculate the mean endothelial cell density.

### Surgical Technique and Postoperative Treatment

All 9 participating surgeons received common training on the study protocol and surgical technique. Investigators selected phakic IOL power to achieve target residual refraction. Power calculations were predicted using the formula originally derived by Van

der Heijde<sup>16</sup> and further refined by Holladay.<sup>17</sup> Iridectomy or iridotomy at the time of surgery was not considered necessary for successful implantation but could be performed at investigator discretion and was done in only 5 of the 190 surgeries (2.6%).

Before surgery, the pupil was constricted (pilocarpine 2% was recommended) to prevent potential contact with the crystalline lens. Investigators administered the anesthesia of their choice (e.g., topical, retrobulbar, peribulbar, or general anesthesia). Investigators determined final lens size by confirming white-to-white measurement of the anterior chamber diameter with calipers, on the sedated eye. In this study, white-to-white measurements plus 0.5 mm determined the overall size of the IOL. The anterior chamber was accessed with a corneal tunnel incision of approximately 3.0 mm oriented temporally, superiorly, or along the steepest axis. Administration of acetylcholine chloride intraocular solution 1% (Miochol-E, Novartis Ophthalmics, East Hanover, NJ) was used when insufficient pupil constriction was observed intraoperatively. To inflate and maintain the chamber, sodium hyaluronate 1% (Provisc, Alcon Laboratories, Inc.) was injected tangentially into the angle, away from the pupil. This cohesive ophthalmic viscoelastic device (OVD) was used to achieve ease of OVD removal after IOL implantation. The AcrySof phakic IOL was loaded into the Monarch II IOL Delivery System with its anterior optic surface facing upward (Fig 2A, available at <http://aaojournal.org>) and was then folded and slowly delivered with the cartridge positioned at midpupil to provide delivery in the area of maximum corneal depth (Fig 2B and video clip, available at <http://aaojournal.org>). After pausing for the leading haptics to unfold, delivery was continued (Fig 2C, available at <http://aaojournal.org>); when the leading haptics reached the distal angle, the cartridge was withdrawn as delivery continued, to avoid increased compression in the distal angle. Trailing haptics were left just outside the incision and then



**Figure 3.** A-D Postoperative images of the AcrySof angle-supported phakic intraocular lens (IOL). A and B, the implanted AcrySof phakic IOL in a nondilated and a dilated eye, respectively. C and D, gonioscopic views of the lens in the anterior chamber angle and the haptic footplate position in the anterior chamber angle, respectively.



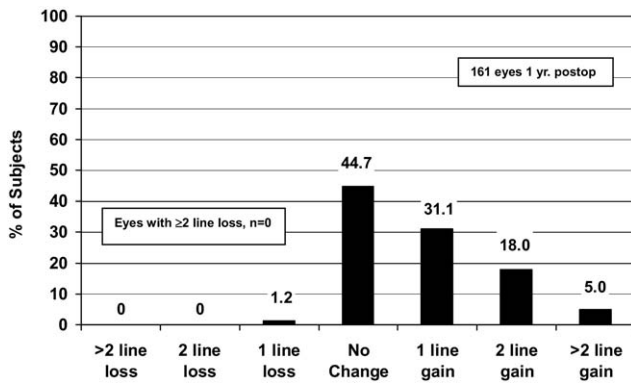


Figure 4. Best-corrected visual acuity 1 year after implantation with the AcrySof phakic angle-supported refractive intraocular lens (IOL).

tucked one at a time into the anterior chamber angle (Fig 2D, available at <http://aaojournal.org>) so that the lens was positioned with all 4 haptics in the anterior chamber (Fig 2E, available at <http://aaojournal.org>). Incision size was confirmed with the gauge or device of the investigators' choice. Lens position and integrity were confirmed as part of the gonioscopic examination before wound closure.

Investigators thoroughly removed the cohesive OVD with irrigation and aspiration devices and techniques of their choice. Passive removal consisted of irrigation via injection of intraocular irrigating solution to displace the OVD through the incision. Active removal included the use of a bimanual or single port system to simultaneously irrigate and aspirate the OVD.

Postoperative images show the implanted AcrySof phakic IOL in a nondilated (Fig 3A) and a dilated (Fig 3B) eye. Gonioscopic views show the lens in the anterior chamber angle (Fig 3C) and the haptic footplate position in the anterior chamber angle (Fig 3D). Closure with sutures was optional. Acetazolamide (Diamox, Lederle Laboratories, Philadelphia, PA) or equivalent was given at the conclusion of surgery to control intraocular pressure (IOP). The operative eye was protected with an eye shield, and subjects were instructed not to rub the eye and to avoid direct eye trauma. Postoperative treatment included an ocular antibiotic and steroid regimen (e.g., prednisolone acetate ophthalmic suspension 1% [Pred Forte, Allergan, Inc., Irvine, CA]) or tobramycin 0.3%/dexamethasone 0.1% [Tobradex, Alcon Laboratories, Inc.] for 1 to 4 weeks.

## Postoperative Evaluations

Subjects were examined on the first postoperative day and 1 week after surgery. Subsequent examinations were performed at 1, 3, 6, and 12 months and included uncorrected and BSCVA, mesopic pupil size, cycloplegic refraction, tonometry (Goldmann applanation method), pachymetry, manual keratometry, slit-lamp examination, dilated fundus examination, gonioscopic examination, endothelial cell density analysis, and a crystalline lens assessment using Lens Opacities Classification System III. Visual acuities, including uncorrected distance visual acuity (UCVA) and BSCVA, were measured to the smallest line using an ETDRS chart at 4 m under photopic conditions. Manifest refraction was performed with the same phoropter or trial frames as were used in preoperative assessments, using a 100% contrast ETDRS chart at 4 m under photopic conditions. Endothelial cell density was assessed 1 month after surgery and at all subsequent examinations in the same manner as was done preoperatively. Intraocular lens position was assessed at each postoperative visit via slit-lamp examination,

using the centerline of the lens (a line along the optic diameter extending across both haptic ramps). Intraocular lens position was recorded in four 15-degree increment categories (i.e., 0–15, 15–30, 30–45, and 45–60 degrees). As part of the ongoing study, subjects will receive examinations every 6 months for the first 3 years after surgery and then annually for an additional 2 years.

## Statistical Analysis

Primary study results were calculated and summarized descriptively (e.g., n, %, mean, standard deviation, range). The overall mean change in endothelial cell density was calculated as the percent change in mean values from the preoperative visit to 1 year after surgery. Intraocular lens position was estimated as a supportive safety outcome. Because statistical analyses were interim descriptive summary results for a single treatment group, a level of statistical significance was not prespecified.

## Results

Results are presented with conformance to the standard format for reporting refractive surgical data described by Koch et al.<sup>18</sup>

### Demographics and Subject Characteristics

Subjects had a mean age of  $35.7 \pm 8.6$  years (standard deviation) ranging from 18 to 53 years; 42% were male and 58% were female, and most were Caucasian ( $n = 187/190$ , 98.4%) (Table 1, available at <http://aaojournal.org>). The mean preoperative MRSE in the operative eye was  $-10.38$  D ( $\pm 2.43$  D) ranging from  $-16.50$  to  $-6.63$  D. The mean lens power of implanted IOLs was  $-11.10 \pm 2.20$  D (range,  $-16.50$  to  $-7.50$  D). A preoperative BSCVA of 20/40 or better was achieved by 99.5% (189/190) of subjects, and 54.7% (104/190) had 20/20 or better.

### Safety

One year postoperatively, no subjects lost 2 or more lines of BSCVA (Fig 4). Many subjects (44.7%,  $n = 72$ ) had no change in lines of BSCVA, 31.1% ( $n = 50$ ) gained 1 BSCVA line, 23.0% ( $n = 37$ ) gained  $\geq 2$  BSCVA lines, and 1.2% ( $n = 2$ ) lost 1 line. The safety index (ratio of mean postoperative BSCVA of 1.15/mean preoperative BSCVA of 0.92) was 1.25.

### Efficacy

One year after surgery, 57.8% of subjects achieved a UCVA of 20/20 or better and 99.4% achieved 20/40 or better (Fig 5). The

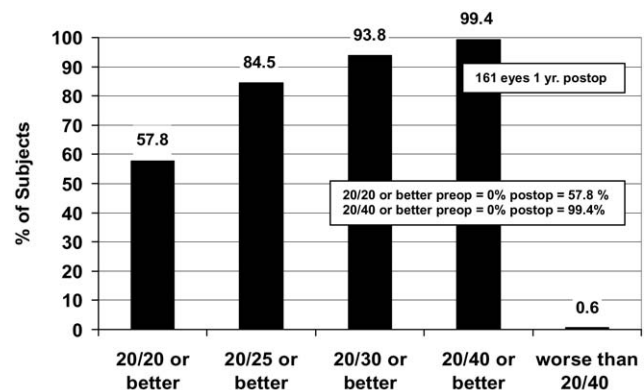


Figure 5. Uncorrected visual acuity 1 year after implantation of the AcrySof phakic angle-supported refractive intraocular lens.

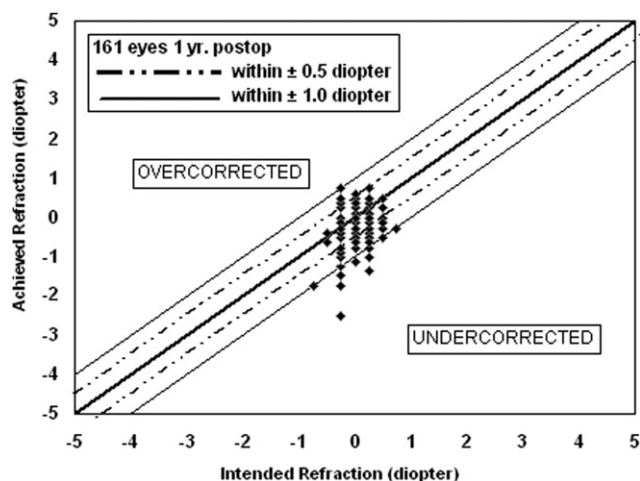


Figure 7. Intended versus achieved refractive error 1 year after implantation with the AcrySof phakic angle-supported refractive intraocular lens.

efficacy index (ratio of mean postoperative UCVA 0.96/mean preoperative BSCVA 0.92) was 1.04. In addition, 100% of subjects achieved a BSCVA of 20/32 or better, and 85.7% achieved 20/20 or better (Fig 6, available at <http://aaojournal.org>).

### Predictability and Stability

The 1-year postoperative mean MRSE was  $-0.23$  D ( $\pm 0.50$  D, range  $-2.50$  to  $0.75$  D). The 1-year intended versus achieved refraction for each subject is illustrated in Figure 7. A residual refractive error within  $\pm 0.50$  D of the targeted refractive error was achieved by 72.7% ( $n = 117$ ) of subjects, and a residual refractive error within  $\pm 1.00$  D of targeted refractive error was achieved by 95.7% ( $n = 154$ ) (Fig 8, available at <http://aaojournal.org>). Most subjects (56%) had a mean postoperative MRSE that was between  $0.00$  D and  $-0.50$  D. Mean MRSE during the study duration is presented in Figure 9. Mean MRSE improved from preoperative values of  $-10.38$  to  $-0.20$  D 1 week after surgery and was stable 6 months ( $-0.21$  D) and 1 year ( $-0.23$  D) after surgery.

### Secondary Surgical Modification and Reversibility

Two subjects underwent secondary surgical interventions. Approximately 5 months after surgery, 1 subject had IOL replacement

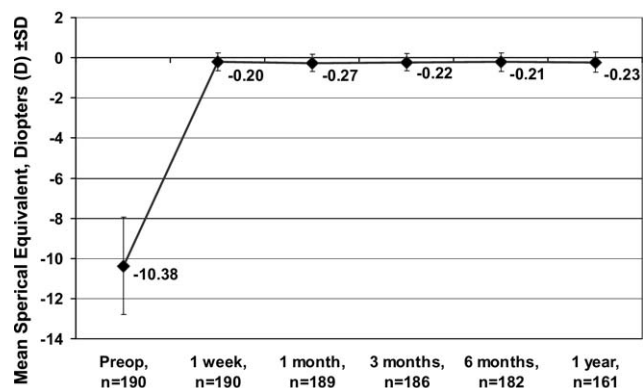


Figure 9. Mean manifest refraction spherical equivalent (MRSE) from before surgery to 1 year after implantation with the AcrySof phakic angle-supported refractive intraocular lens. SD = standard deviation.

Table 2. Adverse Event Incidence Rates

Adverse Event	Incidence Rate N = 190	
	n	%
Increased IOP requiring treatment <sup>a</sup>	6	3.2
Prolonged hospitalization for increased IOP <sup>b,c</sup>	5	2.6
Cataract formation <sup>d</sup>	5	2.6
Corneal haze	1	0.5
Synechia (single-strand)	2	1.1
Secondary surgical intervention		
IOL replacement for power exchange <sup>e</sup>	1	0.5
IOL removal because of upside-down placement	1	0.5
New suturing <sup>e</sup>	1	0.5
Endophthalmitis	0	0
Pupillary block	0	0
Pupil ovalization	0	0
Retinal detachment	0	0

IOL = intraocular lens; IOP = intraocular pressure.

Incidence rates are based on the number of eyes with an event divided by the number of eyes implanted.

<sup>a</sup> $\geq 1$  mo after surgery.

<sup>b</sup>On day of surgery because of retained OVD.

<sup>c</sup>Prolonged hospitalization was defined as a hospital stay  $\geq 24$  hrs beyond the planned stay.

<sup>d</sup>Secondary to concurrent ophthalmic disease ( $n = 2$ ), upside-down IOL implantation ( $n = 2$ ), subject age, and family pathology ( $n = 1$ ).

<sup>e</sup>Observed in the same subject.

with new suturing for power exchange. This subject had an initial postoperative BSCVA of  $-0.04$  logMAR and a postsecondary surgery BSCVA of  $-0.02$  logMAR. One subject had IOL removal 1 day after surgery to correct upside-down lens placement. This subject had an initial postoperative BSCVA of  $-0.10$  logMAR; however, the postsecondary surgery BSCVA is not known, because the subject refused additional examinations and exited the study on the day of secondary surgery.

### Adverse Events

Six subjects had increased IOP requiring treatment at  $\geq 1$  month after surgery for the following reasons: steroid response ( $n = 4$ ), related to surgery ( $n = 1$ ), and at an unscheduled visit for an unknown reason ( $n = 1$ ) (Table 2). Five subjects had increased IOP on the day of surgery because of retained OVD. Five subjects had cataract formation for the following reasons: high myopia and age-related changes ( $n = 2$ ), upside-down IOL implantation ( $n = 2$ ), and subject age and family pathology ( $n = 1$ ). One subject had corneal haze due to surgery; this event

Table 3. Change in Central Endothelial Cell Density from Preoperative Visit to One Year after Surgery

Mean Change in Endothelial Cell Density Category, %	Subjects n (%)	Overall Mean Change, %
Loss $\geq 10$	21 (15.1)	
Loss $< 10$ to $\geq 5$	20 (14.4)	
Loss $< 5$ to gain $< 5$	92 (66.2)	
Gain $\geq 5$ to $< 10$	5 (3.6)	
Gain $\geq 10$	1 (0.7)	
Total	139 (100)	$-4.77 \pm 8.04$

resolved without treatment. Two subjects experienced synechiae considered related to the IOL: 1 subject had 2 single strands, 1 at 5 to 7 o'clock and 1 at 2 o'clock; the other subject had a single strand at 7 to 8 o'clock. Both subjects who had synechiae continued study participation without IOL removal. The synechiae were the only adverse events considered related to the IOL ( $n = 2$ ). No adverse events were ongoing 1 year after surgery. No incidences of pupillary block, pupil ovalization, or retinal detachment were observed.

### Endothelium

Data from 139 subjects met prespecified criteria for statistical analysis of endothelial cell density. The overall mean percentage change in central endothelial cell density from the preoperative visit to 1 year after surgery was  $-4.77\%$  ( $\pm 8.04\%$ ;  $n = 139$ ) (Table 3). For most subjects, the mean change in central endothelial density ranged from a loss of  $<5\%$  to a gain of  $<5\%$  ( $66.2\%$ ,  $n = 92$ ).

### Intraocular Lens Position

Intraocular lens position was calculated in 2 ways: (1) incidence of rotation  $>15$  degrees from baseline at any visit through the 1-year visit and (2) incidence of rotation  $>15$  degrees from the previous visit, at any visit up to 1 year after surgery. The greater proportion of subjects ( $67.4\%$ ,  $n = 128$ ) had  $\leq 15$  degrees IOL rotation from baseline to any visit through 1 year after surgery, and  $32.6\%$  ( $n = 62$ ) had IOL rotation  $>15$  degrees. When IOL position was considered from visit to visit, the greater proportion of subjects ( $71.1\%$ ,  $n = 135$ ) never had an IOL rotation of  $>15$  degrees since their previous visit, and  $28.9\%$  ( $n = 55$ ) had IOL rotations  $>15$  degrees. Intraocular lens rotation was not associated with clinical sequelae.

## Discussion

### Safety and Effectiveness

One year after surgery, the AcrySof phakic angle-supported IOL demonstrated favorable results in all primary outcomes, including BSCVA, UCVA, predictability and stability of MRSE, adverse events, and endothelial cell density. Safety results supported continued follow-up of this phakic IOL. Visual acuity observations were consistent with published reports of phakic IOLs; UCVA and BSCVA results were excellent. In addition, 1-year postoperative MRSE values demonstrated strong predictability, particularly because for most investigators these were the first implants with this new refractive IOL. Adverse events were seldom and generally as expected in the setting of ocular surgery. Several notable adverse events previously associated with phakic IOLs were not observed in this study, such as pupil ovalization, pupillary block, and retinal detachment. Although the study results did not raise safety concerns, ongoing follow-up may identify potentially important events.

### Endothelium

The maintenance of endothelial cell density in 139 subjects observed 1 year after implantation with this angle-supported

phakic IOL was reassuring but merits ongoing evaluation. All subjects, including those with  $\geq 10\%$  endothelial cell density loss 1 year after surgery ( $n = 21$ ,  $15.1\%$ ), will continue to be evaluated in the follow-up period. In the future, ongoing surgical experience with the AcrySof phakic angle-supported IOL may lead to refinements in surgical technique, lessening early endothelial cell density loss. Interpretation of mean percentage changes in endothelial cell density should consider the estimated  $0.6\%$  physiologic age-related annual decrease.<sup>19</sup> Apparent gains in endothelial cell density were possibly related to common measurement or analysis variability and the effects of corneal remodeling in response to wound healing. Other studies have reported similar postoperative cellular activity.<sup>2,12,13</sup>

The 1-year mean percentage change in endothelial cell density of the AcrySof phakic IOL ( $-4.77\pm 8.04\%$ ) was better than the 1-year mean percentage change reported for the currently marketed iris-fixated polymethyl methacrylate Verisyse/Artisan IOL (Advanced Medical Optics, Inc., Santa Ana, CA, and Ophtec BV, Groningen, The Netherlands) ( $-9.39\%$  to  $+0.5\%$  in various studies)<sup>2,5,11,13</sup> and the 1-year mean percentage change of the iris-fixated anterior chamber VeriFlex/ArtiFlex 5- and 6-mm IOLs (Advanced Medical Optics, Inc.) ( $-8.4\%$  and  $-4.06\%$ , respectively).<sup>20</sup> Compared with other anterior chamber angle-supported phakic IOLs, the AcrySof phakic IOL had superior or similar 1-year mean changes in endothelial cell density (Worst-Fechner IOL,  $-13\%$ ;<sup>4</sup> ZB5M and ZB5MF IOLs,  $-5.53\%$ ;<sup>10</sup> Baikoff Model ZB5M IOL,  $-4.3$  to  $-5.3\%$ <sup>1</sup>).

Three-year endothelial cell density results from this study are being collected and evaluated. To date, these long-term results appear reassuring; more definitive results will be available in the future as subjects progress in the study. The long-term results are of great interest, because early angle-supported phakic IOLs had dramatic endothelial cell density losses approximately 3 years after implantation and were withdrawn from the market in France (ICare, Corneal Laboratories, Paris, France; Vivarte/GBR, Zeiss-Mediatech, Jena, Germany). In a long-term study of the ZB5M anterior chamber angle-supported phakic IOL, endothelial cell loss increased over 12 years; authors concluded that annual endothelial cell counts should be required.<sup>6</sup>

### Surgical Considerations

Important factors in the prevention of early postoperative or chronic decreases in endothelial cell density are adequate anterior chamber depth and appropriate preoperative endothelial cell density. Phakic IOL sizing is challenging, because the internal diameter of the anterior chamber varies with the horizontal or vertical axis and undergoes constant modifications as the result of accommodation and aging.<sup>21</sup> Anterior chamber biometry methods that are more advanced than the white-to-white measurement used in this study may improve accuracy in anterior chamber size estimation. A method with acceptable biometric accuracy, availability, and cost has not been firmly established. Options include very high-



frequency ultrasound, the Scheimpflug camera, and anterior segment optical coherence tomography.<sup>22</sup> In particular, the use of anterior chamber optical coherence tomography with defined objective measurements is promising.<sup>21,23</sup> Additional study of the suitability of such methods for clinical use in anterior chamber measurement for phakic IOL sizing is needed.

Improved methods of anterior chamber biometry would also contribute to accurate sizing resulting in improved IOL stability. In this study, IOL rotation was not associated with clinical sequelae 1 year postoperatively. However, several factors limit interpretation of IOL stability in this study. Intraocular lens position was indicated in 15-degree increments, so observer variability in rounding may have led to erroneous observations. Variances in a subject's head tilt on slit-lamp examination may have also confounded IOL position results. Improved precision in IOL position reporting and standardized subject position has been implemented successfully in other studies<sup>24</sup> and may increase the reliability of results in future studies of the AcrySof phakic angle-supported IOL.

Several surgical considerations were regarded as essential. Accurate power calculation was necessary to ensure desired postsurgical refractive results. Proper loading of the injector with the anterior optic surface of the IOL facing upward must be emphasized, because 2 lenses in this study were implanted upside-down, resulting in iatrogenic cataract formation. Subsequent to this study, the IOL has been modified to include side-up indicators that are visible through the injector cartridge (Fig 1). Iridectomy, which was not considered necessary but was permitted, was performed in only 5 of the 190 surgeries (2.6%). Increased IOP occurring soon after implantation tended to be related to retained OVD, whereas elevated IOP of a later onset was more often associated with prolonged steroid administration. These observations underscore the importance of thorough OVD removal and appropriate postoperative medical management.

In conclusion, favorable study findings in all primary outcomes, along with advantages including a small incision size (~3.0 mm) and a simplified operative procedure, support the potential of the AcrySof phakic angle-supported IOL in the correction of moderate-to-high myopia. Clinical outcomes 1 year after surgery were promising; however, further follow-up is needed to investigate the long-term effects of the IOL in the anterior chamber angle. Until further long-term data are available, the plan of care may need to include endothelial cell density monitoring for the duration of the implant. Favorable long-term clinical study results with this hydrophobic refractive IOL, together with advances in IOL design, materials, and anterior chamber biometry, may supersede previous safety concerns associated with other angle-supported phakic IOLs. On the basis of these early observations of excellent refractive correction and predictability with acceptable safety, the AcrySof phakic angle-supported IOL represents a promising future option for the reduction or correction of moderate-to-high myopia.

## References

- Baikoff G, Arne JL, Bokobza Y, et al. Angle-fixated anterior chamber phakic intraocular lens for myopia of -7 to -19 diopters. *J Refract Surg* 1998;14:282-93.
- Benedetti S, Casamenti V, Benedetti M. Long-term endothelial changes in phakic eyes after Artisan intraocular lens implantation to correct myopia: five-year study. *J Cataract Refract Surg* 2007;33:784-90.
- Mimouni F, Colin J, Koffi V, Bonnet P. Damage to the corneal endothelium from anterior chamber intraocular lenses in phakic myopic eyes. *Refract Corneal Surg* 1991;7:277-81.
- Perez-Santonja JJ, Bueno JL, Zato MA. Surgical correction of high myopia in phakic eyes with Worst-Fechner myopia intraocular lenses. *J Refract Surg* 1997;13:268-81.
- Tahzib NG, Nuijts RM, Wu WY, Budo CJ. Long-term study of Artisan phakic intraocular lens implantation for the correction of moderate to high myopia: ten-year follow-up results. *Ophthalmology* 2007;114:1133-42.
- Javaloy J, Alio JL, Iradier MT, et al. Outcomes of ZB5M angle-supported anterior chamber phakic intraocular lenses at 12 years. *J Refract Surg* 2007;23:147-58.
- Baikoff G, Bourgeon G, Jodai HJ, et al. Pigment dispersion and Artisan implants: crystalline lens rise as a safety criterion [in French]. *J Fr Ophthalmol* 2005;28:590-7.
- Brandt JD, Mockovak ME, Chayet A. Pigmentary dispersion syndrome induced by a posterior chamber phakic refractive lens. *Am J Ophthalmol* 2001;131:260-3.
- Martinez-Castillo V, Elies D, Boixadera A, et al. Silicone posterior chamber phakic intraocular lens dislocated into the vitreous cavity. *J Refract Surg* 2004;20:773-7.
- Alio JL, de la Hoz F, Perez-Santonja JJ, et al. Phakic anterior chamber lenses for the correction of myopia: a 7-year cumulative analysis of complications in 263 cases. *Ophthalmology* 1999;106:458-66.
- Landesz M, Worst JG, van Rij G. Long-term results of correction of high myopia with an iris claw phakic intraocular lens. *J Refract Surg* 2000;16:310-6.
- Perez-Santonja JJ, Alio JL, Jimenez-Alfaro I, Zato MA. Surgical correction of severe myopia with an angle-supported phakic intraocular lens. *J Cataract Refract Surg* 2000;26:1288-302.
- Saxena R, Boekhoorn SS, Mulder PG, et al. Long-term follow-up of endothelial cell change after Artisan phakic intraocular lens implantation. *Ophthalmology* 2008;115:608-13.
- Allemann N, Chamon W, Tanaka HM, et al. Myopic angle-supported intraocular lenses: two-year follow-up. *Ophthalmology* 2000;107:1549-54.
- Chylack LT Jr. Instructions for applying the Lens Opacities Classification System, version III (LOCS III). Boston, MA: Center for Ophthalmic Research, Brigham and Women's Hospital; 2001:112.
- Van der Heijde GL. Some optical aspects implantation of an IOL in an myopic eye. *Eur J Implant Refract Surg* 1989;1:245-8.
- Holladay JT. Standardizing constants for ultrasonic biometry, keratometry, and intraocular lens power calculations. *J Cataract Refract Surg* 1997;23:1356-70.
- Koch DD, Kohnen T, Obstbaum SA, Rosen ES. Format for reporting refractive surgical data. *J Cataract Refract Surg* 1998;24:285-7.
- Bourne WM, Nelson LR, Hodge DO. Central corneal endothelial cell changes over a ten-year period. *Invest Ophthalmol Vis Sci* 1997;38:779-82.

20. Guell JL, Morral M, Gris O, et al. Five-year follow-up of 399 phakic Artisan-Verisyse implantation for myopia, hyperopia, and/or astigmatism. *Ophthalmology* 2008;115:1002–12.
21. Baikoff G. Anterior segment OCT and phakic intraocular lenses: a perspective. *J Cataract Refract Surg* 2006;32:1827–35.
22. Couillet J, Mahieu L, Malecaze F, et al. Severe endothelial cell loss following uneventful angle-supported phakic intraocular lens implantation for high myopia. *J Cataract Refract Surg* 2007;33:1477–81.
23. Kohnen T, Thomala MC, Cichocki M, Strenger A. Internal anterior chamber diameter using optical coherence tomography compared with white-to-white distances using automated measurements. *J Cataract Refract Surg* 2006;32:1809–13.
24. Baumeister M, Bühren J, Kohnen T. Position of angle-supported, iris-fixated, and ciliary sulcus-implanted myopic phakic intraocular lenses evaluated by Scheimpflug photography. *Am J Ophthalmol* 2004;138:723–31.

## Footnotes and Financial Disclosures

---

Originally received: August 13, 2008.

Final revision: January 27, 2009.

Accepted: January 27, 2009.

Available online: May 30, 2009.

Manuscript no. 2008-973.

<sup>1</sup> Johann Wolfgang Goethe-University, Department of Ophthalmology, Frankfurt/Main, Germany.

<sup>2</sup> FreeVis LASIK Center, University Eye Clinic Mannheim, Mannheim, Germany.

<sup>3</sup> CHU Morvan, Service Ophtalmologie, Brest, France.

<sup>4</sup> Eye clinic Ahaus, Ahaus, Germany.

<sup>5</sup> Hôpital Purpan, Service d'Ophtalmologie, Toulouse, France.

<sup>6</sup> Groupe Hospitalier Pellegrin, Service d'Ophtalmologie, Bordeaux, France.

<sup>7</sup> Instituto Oftalmológico de Alicante, Alicante, Spain.

<sup>8</sup> Unità Operativa di Oculistica, Verona, Italy.

<sup>9</sup> Hospital General Santo Antonio, Porto, Portugal.

The study group is available in Appendix 1 at <http://aaojournal.org>.

Presented in part at: the American Academy of Ophthalmology annual meeting, November 2006, Las Vegas, Nevada.

Financial Disclosure(s):

The author(s) have made the following disclosure(s):

Michael C. Knorz is a paid consultant for Alcon Inc. and AMO Inc.

Thomas Kohnen is a paid consultant for Alcon Inc.

Jean L. Arné is a paid consultant for Alcon Inc.

Beatrice Cochener is a paid consultant for Alcon Inc., AMO Inc., Bausch & Lomb, and THEA.

Joseph Colin is a paid consultant for Alcon Inc.

Jorge L. Alió is a paid consultant for Alcon Inc.

Supported by Alcon Laboratories, Inc., Fort Worth, Texas, as a clinical investigational project.

Correspondence:

Thomas Kohnen, MD, Professor of Ophthalmology, Johann Wolfgang Goethe-University, Department of Ophthalmology, Theodor-Stern-Kai 7, 60590 Frankfurt am Main, Germany. E-mail: [kohnen@em.uni-frankfurt.de](mailto:kohnen@em.uni-frankfurt.de).

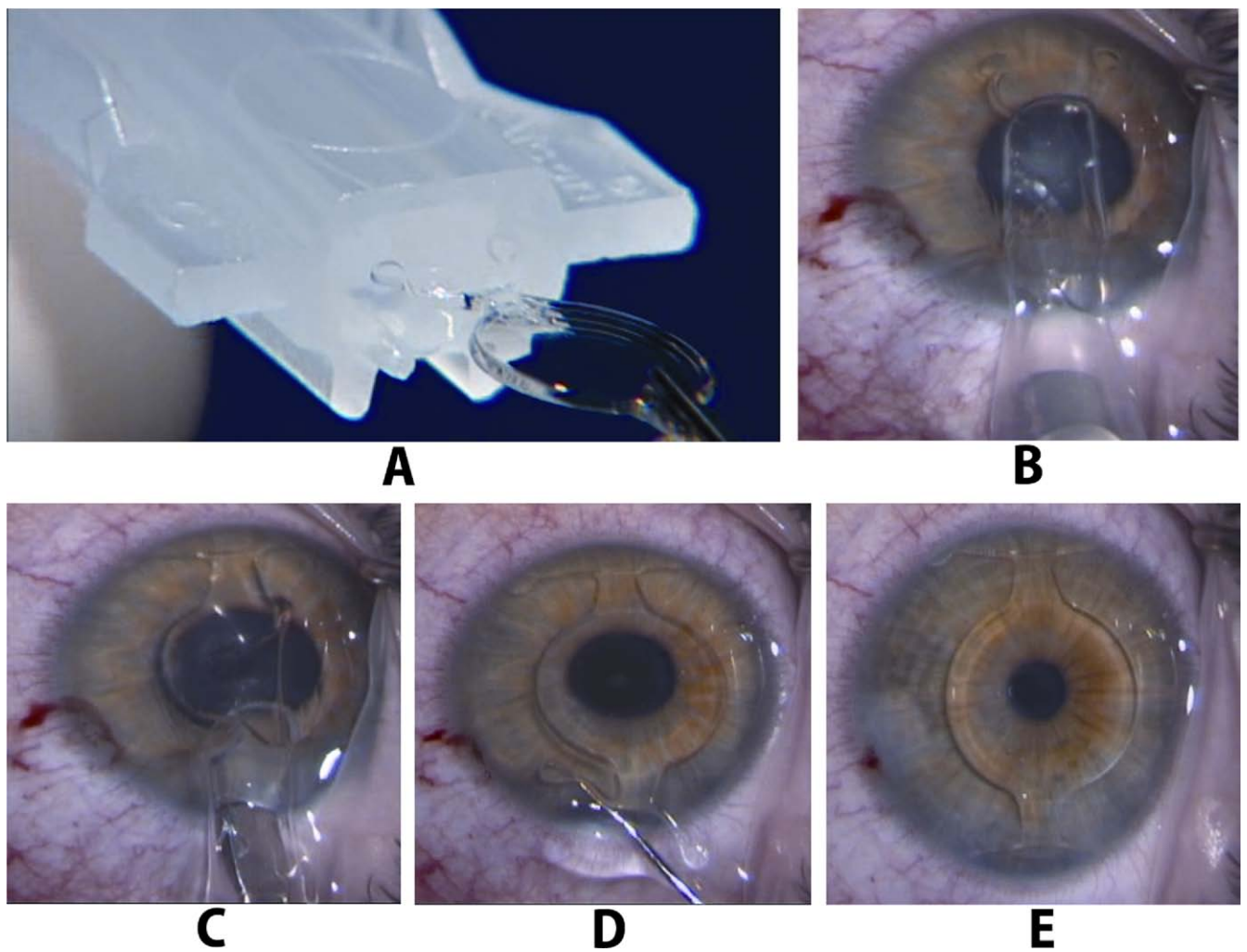


## Appendix 1. Multicenter European Study Group

---

Magdalena Cichocki, MD, Christoph Kühne, MD, Evdokia Terzi, MD, Tanja Wiegand (Department of Ophthalmology, Johann Wolfgang Goethe-University, Frankfurt am Main, Germany); José Luis Güell (Instituto de Microcirugia Ocular, Barcelona, Spain), Stefan Häsemeyer, MD (FreeVis Lasik-Zentrum, Universitäts-Augenklinik, Mannheim, Germany); Christine Tanguy-Gueguen, Stephane Lebaillif, MD (CHU Morvan, Brest, France); Stefanie Schmickler, MD, Diana

Laukötter, Susanne Barte-Lohmann (Augenklinik Ahaus, Ahaus, Germany), Catherine Garabétian, Pierre Fournié, MD, Laurence Mahieu, MD, Corinne Rumebe (CHU Purpan, Toulouse, France); Concepción de la Vega, MD, Tomas Javaloy, MD, Esperanza Sala (Vissum-IOA, Alicante, Spain); Jérôme Guinguet, Sylvie Simonpoli, MD, (CHU Bordeaux-Hospital Pellegrin, Bordeaux, France); Simonetta Morselli, MD, Nicola Dalla Pellegrina, MD (Ospedale Borgo Trento, Verona, Italy); Fernando Vaz, MD, Teresa Pacheco, MD, Bernadette Pessoa, MD, Marta Macedo, MD, and Miguel Gomes, MD (Hospital Geral Santo Antonio, Porto, Portugal).



**Figure 2.** Implantation of the AcrySof angle-supported phakic intraocular lens (IOL). **A**, The lens is loaded into the Monarch II IOL Delivery System with the anterior surface facing upward. **B**, The lens is folded and slowly delivered with the cartridge positioned at midpupil. **C**, Delivery continues with unfolding of the lens. **D**, Trailing haptics are tucked one at a time into the anterior chamber angle. **E**, The lens is positioned with all 4 haptics in the anterior chamber angle.

Table 1. Demographics and Subject Characteristics

Demographic/Subject Characteristic	Value
No. of subjects (eyes)	190 (190)
Age (yrs)	
Mean±SD	35.7±8.6
Range	18–53
Gender, n (%)	
Female	110 (58)
Male	80 (42)
Race, n (%)	
Caucasian	187 (98)
African American	1 (1)
Hispanic	2 (1)
Preoperative MRSE (D)	
Mean±SD	-10.38±2.43
Range	-16.50 to -6.63
Implanted IOL power (D)	
Mean±SD	-11.1±2.2
Range	-16.5 to -7.50
Implanted IOL model, n (%)	
L12500 (12.5 mm OAL)	66 (34.7)
L13000 (13.0 mm OAL)	90 (47.3)
L13500 (13.5 mm OAL)	34 (17.9)

D = diopter; IOL = intraocular lens; MRSE = manifest refraction spherical equivalent; OAL = overall length; SD = standard deviation.

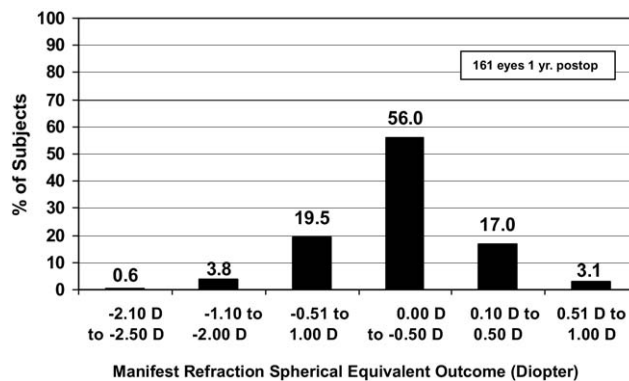


Figure 8. Residual refractive error 1 year after implantation with the AcrySof phakic angle-supported refractive intraocular lens.

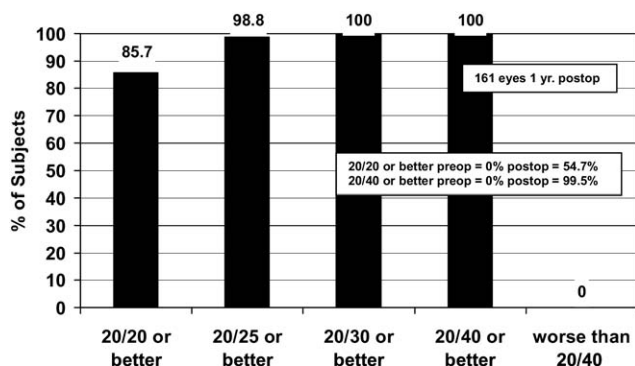


Figure 6. Best-corrected visual acuity 1 year after implantation of the AcrySof phakic angle-supported refractive intraocular lens.